



SCLEROMYOSITIS: A SPECIFIC MUSCLE MANIFESTATION OF SCLERODERMA

Dr. Océane Landon-Cardinal, MD,
Rheumatologist, clinician researcher at the CHUM



Scleroderma is a disease characterized by abnormalities in the functioning of small blood vessels and the immune system, ultimately leading to inflammation and excessive fibrosis (hardening) of the skin and various organs. When the inflammation reaches the muscles of scleroderma patients, it is called "scleromyositis". Scleroderma patients frequently report weakness, which may be due to a variety of causes (e.g., skin thickening, joint contractures, heart or lung involvement, and deconditioning). Weakness due to muscle inflammation (myositis) can therefore easily be missed.



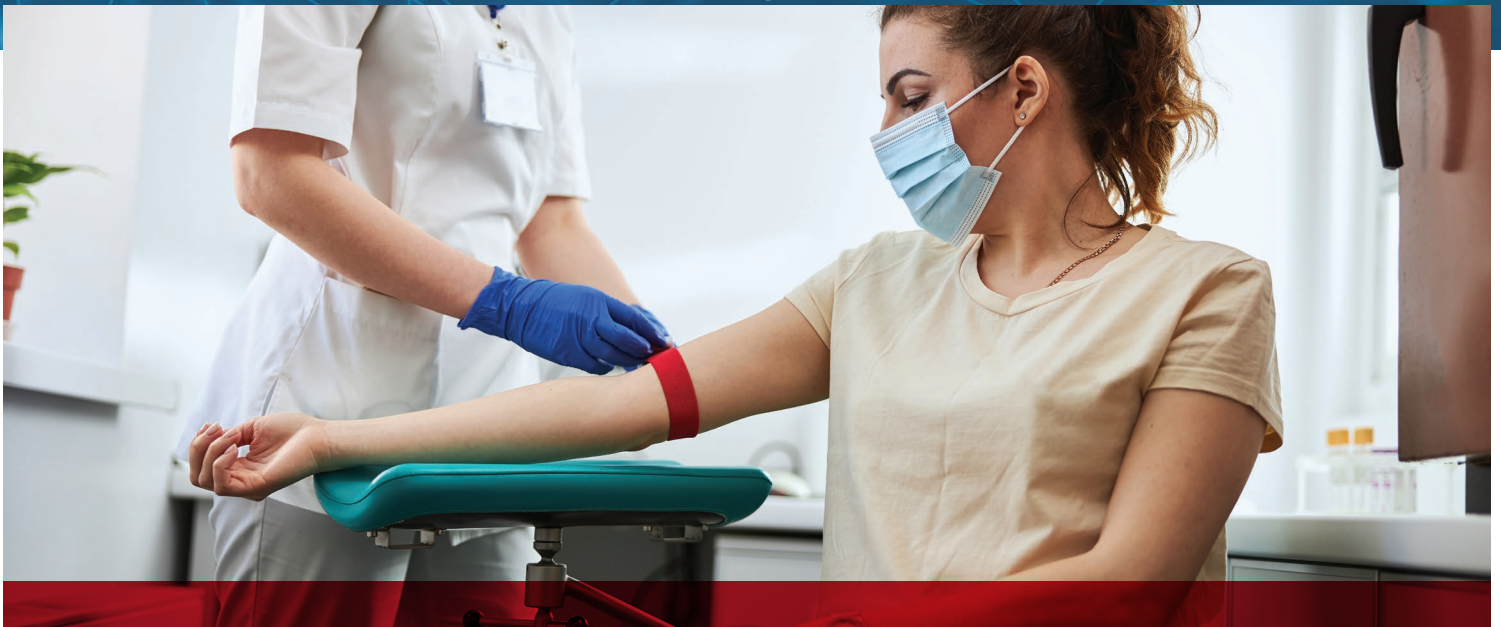WHAT ARE THE SYMPTOMS OF SCLEROMYOSITIS?

MUSCLE WEAKNESS:

The main symptom of myositis is usually muscle weakness, mainly in the shoulders and hips. People with myositis may have difficulty lifting their arms above their shoulders, lifting heavy objects, climbing stairs or getting up from a seat. Neck and back muscles may also be involved with difficulty lifting the head from a pillow or holding the head upright (dropped head). In some cases, the swallowing muscles are involved resulting in difficulty swallowing food.

RAYNAUD'S PHENOMENON:

Scleromyositis is often associated with a discoloration (successively white, blue and/or red) of the fingertips caused, in particular, by cold exposure. [Raynaud's phenomenon](#) is often the first clinical manifestation of scleroderma and may precede the onset of myositis by several years.



OTHER SCLERODERMA MANIFESTATIONS:

All the usual organ involvement of [scleroderma](#) can be found in scleromyositis. It should be noted, however, that the classic skin thickening of scleroderma is not always present at the time of onset of myositis, which may result in a delay in diagnosis.

CARDIOPULMONARY SYMPTOMS:

Myositis can weaken the muscles needed to breathe and cause shortness of breath. Some people may also develop inflammation and/or [fibrosis of the lungs](#), which can contribute to shortness of breath and coughing. More rarely, myositis can cause inflammation of the [heart muscle](#) ("myocarditis") and eventually lead to heart rhythm problems ("arrhythmia") or heart weakness ("heart failure") which can cause shortness of breath or swelling of the legs.

JOINT PAIN/SWELLING:

Occasionally, inflammation of the small joints of the hands may precede or accompany muscle weakness.

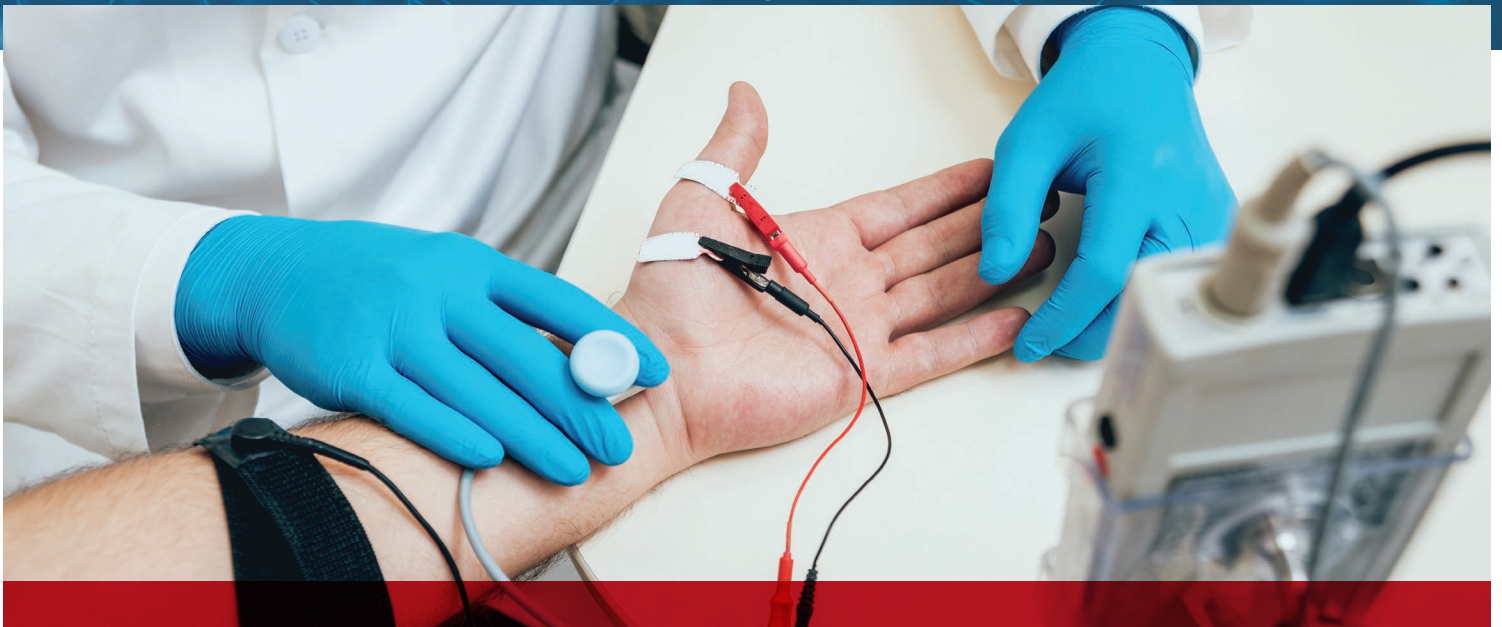
HOW IS SCLEROMYOSITIS DIAGNOSED?

DETAILED QUESTIONNAIRE AND PHYSICAL EXAMINATION:

- ▶ Assessment of muscle strength
- ▶ Evaluation for cutaneous signs of scleroderma (e.g., skin thickening, vessel abnormalities visible at the nailfold)
- ▶ Cardiopulmonary examination
- ▶ Evaluation for joint pain and/or swelling

LABORATORY TESTS:

- ▶ **Muscle enzymes:** Measurement of creatine kinase (CK) or other muscle enzymes (AST, ALT, LD, aldolase) that may be increased following muscle injury. These markers are however not specific for myositis and may be increased in the blood for other reasons.
- ▶ **Autoantibody assay:** The presence of auto-immune markers in the blood may be useful in supporting a diagnosis of myositis, predicting associated organ involvement, and predicting a patient's response to certain treatments. However, it should be noted that autoantibodies in scleroderma are not found in all patients.



ELECTROMYOGRAM (EMG):

EMG measures electrical activity in the muscles using electrodes applied to the skin and may be abnormal in scleromyositis.

MAGNETIC RESONANCE IMAGING (MRI):

MRI is an imaging technique that uses magnetic fields rather than radiation to produce an image of the muscles. It can detect inflammation and muscle damage that may result from myositis.

MUSCLE BIOPSY:

The muscle biopsy consists of taking a small piece of muscle tissue (usually from the shoulder or thigh) under local anesthesia, which is then examined under a microscope.

Recent research has identified abnormalities of small blood vessels (capillaries) in muscle biopsies from patients with scleromyositis. The presence of multiple layers ("reduplication") in the wall ("basement membrane") of the majority of capillaries assessed in muscle biopsies is specifically found in scleromyositis. Identification of these vascular abnormalities, in addition to other autoimmune markers, on muscle biopsy is useful to support a diagnosis of scleromyositis, even when the patient does not have other scleroderma manifestations, including the classic skin thickening of sclerodermas.

CAPILLAROSCOPY:

[Capillaroscopy](#) is a simple and painless examination performed on the hands to look for abnormalities in the small blood vessels called capillaries, located at the nailfold.

CARDIAC INVESTIGATIONS:

Additional tests such as an electrocardiogram (ECG), cardiac ultrasound or cardiac MRI will help to assess the presence and severity of [cardiac involvement](#).

PULMONARY INVESTIGATIONS:

Additional tests such as a pulmonary function tests or a chest CT scan will help to assess the presence and severity of [pulmonary involvement](#).

GASTROINTESTINAL INVESTIGATIONS:

Additional tests to evaluate the esophagus, stomach, small intestine and large intestine will help to assess the presence of various [digestive system disorders](#) associated with scleroderma.

All or some of these different diagnostic tools can be implemented by your treating physician depending on your situation.

SCLEROMYOSITIS: A SPECIFIC MUSCLE MANIFESTATION OF SCLERODERMA

WHAT ARE THE TREATMENTS FOR SCLEROMYOSITIS?

Myositis can be treated with immunosuppressive drugs and muscle rehabilitation.

Immunosuppressive drugs will help regulate the immune system and block muscle inflammation. Current data suggest that these treatments are most effective in inflammatory muscle disease and less effective in fibrosing forms. Muscle biopsy is therefore very important for diagnosis but also to help guide treatment and anticipate the clinical response of patients. Immunosuppressive drugs are usually administered in combination with corticosteroids (cortisone), initially at a high dose and then gradually reduced.

High doses of corticosteroids are associated with an increased risk of developing a scleroderma [renal crisis](#), a rare but urgent complication of scleroderma, which is caused by an acute decrease in blood flow to the kidneys and rapidly leading to their loss of function. Clinical factors such as the disease duration, the form of scleroderma (diffuse vs. limited) and the autoantibody profile will allow the physician to assess which patients are most at risk of developing this complication. Monitoring of certain symptoms and blood pressure at home will be recommended while taking corticosteroids. If the risk of a scleroderma renal crisis is considered too high, the doctor may suggest a blood product called intravenous immunoglobulin for a few months to allow the dose of corticosteroids to be lowered.

Muscle rehabilitation with physical therapy is an important aspect of scleromyositis patients treatment and is aimed at reducing inflammation and rebuilding muscle strength.

Text translated from French by Claude Taillefer, Ph.D., epidemiologist-mathematician.

When muscle disease is very active, a light exercise program is usually recommended. Once inflammation is under control, muscle training should be intensified to prevent loss of strength and endurance. With the guidance of a physician and a physiotherapist, patients can be directed to an exercise program that is appropriate for their cardiorespiratory capacities.

IN SUMMARY

Scleromyositis is a muscular manifestation of systemic scleroderma and may be the earliest feature of the disease. Weakness may be multifactorial and careful evaluation must be performed to make the diagnosis of scleromyositis and provide optimal patient management.

The identification of specific vascular abnormalities on muscle biopsy is useful to support an early diagnosis of scleromyositis especially when the patient does not have other scleroderma manifestations, including scleroderma skin thickening, or scleroderma autoantibodies.



Visit the www.sclerodermie.ca/en/ to see the reference for each sheet highlighted in blue in this document.

A huge Thank You to



The production of this educational sheet was made possible thanks to an educational grant from our partner Boehringer Ingelheim Canada Ltd.